

WISSENSCHAFTLICHE KURZMITTEILUNGEN

Aspects of nasal gland function in the opossum (*Didelphis virginiana* Kerr, 1792) as indicated by carbohydrate histochemistry

By W. MEYER and A. TSUKISE

Institut für Zoologie, Tierärztliche Hochschule Hannover, FRG; and Department of Veterinary Anatomy, College of Agriculture and Veterinary Medicine, Nihon University, Fujisawa, Japan

Receipt of Ms. 30. 01. 1990

Acceptance of Ms. 1. 3. 1990

In the opossum (*Didelphis virginiana* Kerr), a rather basic species, the general pattern of mammalian nasal gland types in the regio respiratoria is already present. Relatively early in nasal cavity development of this animal, the glandulae nasales laterales and the glands of Jacobson's organ can be distinguished, whereas the glandulae nasales mediales (GNM) appear later (TSUDA 1924), probably latest in all mammals (BROMAN 1921). The overall organization and arrangement of these glands in the nasal septum mucosa of the opossum compares closely to that found in Rodentia (Fig. 1; see also BOJSEN-MØLLER 1964). In this connection, using nasal septum samples from six adult animals of both sexes, the present study focusses on carbohydrate histochemical peculiarities of the GNM as, probably, related to specific glandular functions. The methods applied are described in detail by MEYER and TSUKISE (1989), including the control of lectin residue demonstration by addition of inhibitory sugars to the respective lectin solution (see Table).

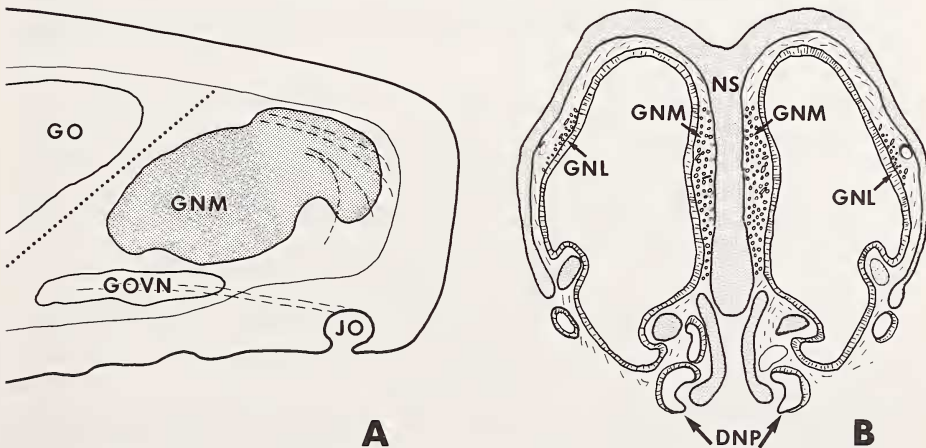


Fig. 1. Position of the GNM at the nasal septum. A: lateral view in regio respiratoria, B: frontal section through nasal cavity; schematically after TSUDA (1924) and original. DNP = ductus nasopalatinus, GNL = glandulae nasales laterales, GNM = gll. nasales mediales, GO = gll. olfactoriae (Bowman's glands), GOVN = gll. organi vomeronasalis, JO = Jacobson's organ, NS = nasal septum

Carbohydrate histochemical reactions in the glandulae nasales mediales of the opossum

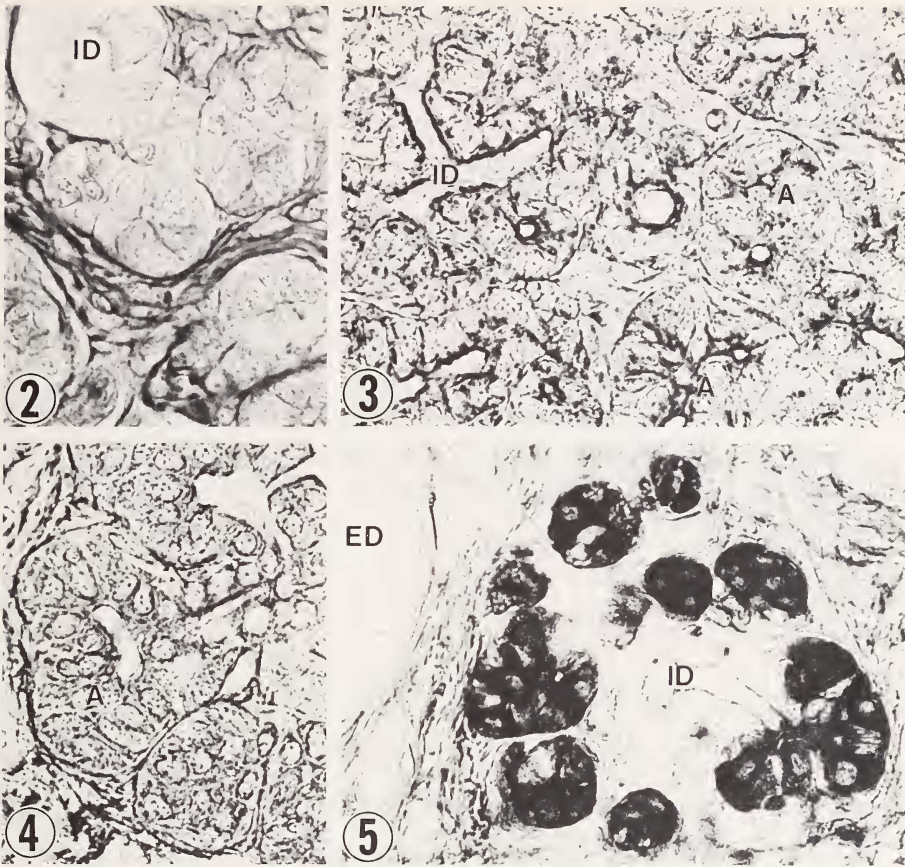
Reactions	Secretory cells	Luminal secretion	Excretory duct cells	Inhibitory sugars for lectins
PAS	2	0	0	
AB (pH 1.0)	0	0	0	
AB (pH 2.5)	0-1	1	0	
DI-FCY	1	1	1	
AB (pH 2.5)-PAS	2	0	0	
Sul-AB (pH 1.0)	2-3	0-1	0	
Amyl-PAS	2	0	0	
PO-Con A-DAB	2-3	2	3 ^a	D-Man
PO-RCA-I-DAB	1-4	3-4	3-4 ^a	D-Gal
PO-PNA-DAB	2-3	2-3	2-3 ^a	D-Gal
PO-SBA-DAB	1-2	3-4	3-4 ^a	D-GalNAc=D-Gal
PO-MPA-DAB	1-2	2-3	1-2 ^a	D-Gal
PO-DBA-DAB	0	0	0	D-GalNAc
PO-UEA-I-DAB	4-5	1	0	L-Fuc
PO-WGA-DAB	1-2	1-2	1-2 ^a	D-Glc
PO-LPA-DAB	2	2	1-3 ^a	NeuNAc

Reaction intensities: 0 = no reaction, 1 = very weak, 2 = weak, 3 = moderate, 4 = strong, 5 = very strong. a: free surface only in collecting duct system.

The GNM of the opossum consist of cells which are located in acini and can be identified as serous type from their fine cytoplasmic granules and the central or slightly basal, roundish nucleus. The serous acini are connected by short intercalated ducts which penetrate partially into the acini, in this way producing centro-acinar cells (Figs. 2-5). The intercalated ducts drain into smaller and larger interlobular ducts with a single-layered epithelium. Typical striated ducts, as known, for example, of mammalian salivary glands, could not be detected. The glandular components are generally surrounded by many blood capillaries and numerous mast cells. The reactions for the different carbohydrate histochemical staining procedures, as summarized in the Table, demonstrated some neutral, but only very few acidic glycoproteins in the GNM (Fig. 2). This is in general accordance with observations from serous or seromucous glands of human nasal mucosa or nasolabial glands of different mammals (THAETE et al. 1981; TSUKISE et al. 1988; MEYER and TSUKISE 1989). However, in the opossum, the serous cells reacted negatively for glycogen.

The lectin reaction pattern in the GNM showed certain similarities to mammalian salivary and nasolabial glands (LADEN et al. 1984; TSUKISE et al. 1988; MEYER and TSUKISE 1989), with the following spectrum of terminal saccharide residues: α -D-mannose, α -D-galactose, β -D-galactose, β -D-galactose-D-N-acetyl-galactosamine, α -L-fucose, sialic acid. This is especially true of the presence of α -L-fucosyl residues in the serous cells, a feature also observed in this cell type in other mammalian glands (MAZZUCA et al. 1982; LADEN et al. 1984; TSUKISE et al. 1988). In the opossum, the respective UEA-I reaction is very strong, particularly in the cell wall or, possibly, in intercellular material (Fig. 5). The significance of such an abundance of fucose in serous cells or their cell walls, respectively, is unknown but the relative hydrophobicity of this sugar may, to some extent, be correlated with specific cellular or membrane transport functions (SCHULTE et al. 1985). Thus, the reaction for UEA-I may be typical for serous cells during active secretion production, and generally affirm the basic role of serous gland cells in water and ion transport (THAETE et al. 1981).

These observations could be related to general functions of the secretion type produced by such glands, as to dilute mucus in ciliated areas of the nasal cavity or to humidify the air stream and the snout surface. Considering, however, the specific structure of the opossum



Figs. 2-5. 2: Alcianblue (pH 2.5) - PAS; 3: PO-RCA-I-DAB; 4: PO-PNA-DAB; 5: PO-UEA-I-DAB. A = acini, ED = excretory duct, ID = intercalated ducts; (all 340 \times)

snout with a deep medial cleft leading into Jacobson's organ (MEYER and TSUKISE 1990), the nonviscous serous fluid of the GNM flowing down could also carry smelling substances which would be sucked into the organ for an additional olfactory evaluation. This may be particularly important for nocturnal animals such as the opossum, a species that needs excellent olfactory properties in discriminating many possible food sources.

Acknowledgement

The skillful technical assistance of Mrs K. BOSCH and Mrs B. HASSFURTHER is gratefully acknowledged.

References

- BOJSEN-MØLLER, F. (1964): Topography of the nasal glands in rats and some other mammals. *Anat. Rec.* 150, 11-24.
- BROMAN, I. (1921): Über die Entwicklung der konstanten größeren Nasenhöhlendrüsen der Nagetiere. *Z. Anat. Entw.gesch.* 60, 439-586.
- LADEN, S. A.; SCHULTE, B. A.; SPICER, S. S. (1984): Histochemical evaluation of secretory glycoproteins in human salivary glands with lectin-horseradish peroxidase conjugates. *J. Histochem. Cytochem.* 32, 965-972.

- MAZZUCA, M.; LHERMITTE, M.; LAFITTE, J. J.; ROUSSEL, P. (1982): Use of lectins for detection of glycoconjugates in glandular cells of the human bronchial mucosa. *J. Histochem. Cytochem.* **30**, 956-966.
- MEYER, W.; TSUKISE, A. (1989): Histochemistry of glycoconjugates in the skin of the bovine muzzle, with special reference to glandular structures. *Acta anat.* **136**, 226-234.
- MEYER, W.; TSUKISE, A. (1990): Structural and histochemical aspects of the snout skin of the opossum (*Didelphis virginiana* Kerr). *Zool. Science* (in press).
- SCHULTE, B. A.; SPICER, S. S.; MILLER, R. L. (1985): Lectin histochemistry of secretory and cell-surface glycoconjugates in the ovine submandibular gland. *Cell. Tiss. Res.* **240**, 57-66.
- THAETE, L. G.; SPICER, S. S.; MILLER, R. L. (1981): Histology, ultrastructure and carbohydrate cytochemistry of surface and glandular epithelium of human nasal mucosa. *Am. J. Anat.* **162**, 243-263.
- TSUDA, S. (1924): Beitrag zur Entwicklungsgeschichte und zum Baue der Nasenhöhle der Marsupialier. *Z. Anat. Entw.gesch.* **70**, 489-511.
- TSUKISE, A.; FUJIMORI, O.; YAMADA, K. (1988): Histochemistry of glycoconjugates in the goat nasolabial skin with special reference to eccrine glands. *Acta anat.* **132**, 150-158.

Authors' addresses: Prof. Dr. WILFRIED MEYER, Institut für Zoologie, Tierärztliche Hochschule Hannover, Bünteweg 17, D-3000 Hannover 71, F.R. Germany; Prof. Dr. AZUMA TSUKISE, Department of Veterinary Anatomy, College of Agriculture and Veterinary Medicine, Nihon University, Fujisawa, Kanagawa, Japan